

An unusual case with a challenging combination of glaucoma, keratoconus, and ocular surface disease

Gayathri Sreekanth, Nicky Jones

ABSTRACT

A 64-year-old gentleman presented for the first time with severe pain, redness, and blurred vision in his left eye with examination revealing corneal hydrops. Discussion with the patient revealed a complex history of bilateral keratoconus and glaucoma. He also had chronic kidney disease, diabetes, Parkinson's, and mental health conditions. Management of the patient involved a delicate balance between building enough trust to allow examination of the anxious patient without pushing too hard that he would not come back for treatment. Treatment was further complicated when he developed Herpes Simplex Keratitis and a rise in his intraocular pressures. The patient was not comfortable being in a hospital environment as he felt that he would "catch something," he would also refuse some examinations and tests. However, with a gentle approach and support from occupational therapy and community nursing teams, a way forward was found that enabled him to remain living independently.

Keywords: Anterior surface disease, Anxiety, Glaucoma

How to cite this article

Sreekanth G, Jones N. An unusual case with a challenging combination of glaucoma, keratoconus, and ocular surface disease. *Edorium J Ophthalmol* 2022;5(2):1–4.

Article ID: 100006O02GS2022

doi: 10.5348/100006O02GS2022CR

INTRODUCTION

Ophthalmology is an intricate science combining many branches of medicine and advancing technology in a way that is rewarding to both patient and ophthalmologist. It is not uncommon for the ophthalmologist to see a patient with an acute eye condition that on further examination becomes a complex case of co-morbidities that pose a significant challenge.

Keratoconus is a rare asymmetrical condition of unknown cause. Those with the condition experience blurred vision and discomfort due to progressive thinning and protrusion of the cornea which may, in around a fifth of cases, require transplantation to maintain vision [1]. Dry eye disease is common in association with keratoconus due to reduced mucin production [2]. Glaucoma affects more than 70 million people worldwide and is a leading cause of irreversible sight loss. The only treatment is to lower the intraocular pressure, usually with topical hypotensive drops but laser trabeculoplasty and glaucoma surgeries such as trabeculectomy and drainage devices are also used, particularly for those patients on maximal therapy [3].

A combination of these conditions makes their management somewhat tricky. This case describes a gentleman with complex systemic, psychological, and

Gayathri Sreekanth¹, Nicky Jones²

Affiliations: ¹FRCO FRCOphth, Specialty Doctor in Ophthalmology, Ophthalmology Department, Glangwili General Hospital, Carmarthen, Carmarthenshire, UK; ²BSc(Hons) MCOptom, PGCert, Prof Cert Glauc, Prof Cert Med Ret, Prof Cert Paed Eyecare, Specialist Optometrist, Ophthalmology Department, Glangwili General Hospital, Carmarthen, Carmarthenshire, UK.

Corresponding Author: Nicky Jones, Specialist Optometrist, Ophthalmology Department, Glangwili General Hospital, Dolgwilli Road, Carmarthen, Carmarthenshire SA31 2AF, UK; Email: nicky.jones5@wales.nhs.uk

Received: 30 May 2022

Accepted: 19 August 2022

Published: 13 September 2022

ocular disease. It shows that we need to look at the patient in front of us as a whole and work with a patient centered approach to find the most appropriate treatment for their condition.

CASE REPORT

A 64-year-old male presented at eye casualty in 2015 with severe pain, redness, watering, and blurred vision in his left eye. Visual acuity in the right eye (RE) was 6/6 and 6/36 (6/24 Pinhole) in the left eye (LE). The patient had recently moved to the area, lived alone and suffered with paranoia and severe anxiety. A report was obtained from his previous optometrist whom the patient trusted and consented to pass on his information.

His ocular history was positive for bilateral advanced keratoconus, RE corneal graft in 2005 and LE managed conservatively with scleral contact lens. He was myopic and astigmatic due to the keratoconus but corrected vision with scleral contact lenses had previously been stable at RE 6/6 and LE 6/9. The patient also had steroid-induced glaucoma treated with Trusopt twice daily and Monopost once daily to both eyes. He also used ocular lubricants regularly for several years. Pressures reported to be in the “mid-teens.”

The patient had a systemic history of chronic kidney disease, type 2 diabetes, hypertension, and Parkinson's disease (with resting tremors) treated with tablet medication for all. He had asthma for which he had two types of inhalers and several allergies including previous severe reaction to Acetazolamide. He had diagnosed mental health conditions but was on no treatment for this.

Examination of the patient showed LE epiphora, conjunctival hyperemia, and corneal opacification at the inferior mid cornea involving the pupil, visible break in Decemet's membrane, significant stromal edema, and inferior conical protrusion. Anterior chamber was negative for cells and flare although difficult to examine. A diagnosis of hydrops was made.

Right eye corneal graft was clear with no signs of inflammation or rejection and a central corneal thickness of 612 μm . Fundus examination showed cup to disc (C:D) ratio of RE 0.5 and LE 0.6, with superior rim thinning, but was otherwise unremarkable. It was not possible to obtain optical coherence tomography (OCT) images to further assess the glaucoma status due to patient anxiety.

Initial treatment plan was topical corticosteroid drops 2 hourly, sodium chloride 5% drops four times daily, and Cyclopentolate 1% drops three times daily to the left eye. He was also advised to continue with anti-glaucoma drops and ocular lubricants. There was concern as to whether the patient would be able to manage this complex treatment regimen given his manifest tremors. However, when offered admission to the ward or for a carer to visit, this was refused, and the patient became anxious about “cross infection.” It was agreed that he will return home with open access to the ward if required.

Follow-up examination was difficult. The patient refused to remove his right contact lens for intraocular pressure (IOP) measurement as he felt it would become lost or damaged and he had no spare. As the vision was poor in the left eye he was anxious not to do anything to risk the right eye vision. Rather than cause further distress, IOP measurement was performed with rebound tonometry. RE 46 mmHg (i-Care tonometer) over the scleral contact lens (no known correction factor) and LE 32 mmHg (Goldmann applanation). It appeared that there was a steroid response to the topical corticosteroid drops, therefore, they were rapidly tapered. Iopidine drops three times daily were added to the existing glaucoma treatment regimen meaning the patient was on maximal treatment.

Two weeks later, the pressures had reduced to RE 30 mmHg (i-Care over scleral contact lens) and LE 23 mmHg (Goldmann). Surgical management of the glaucoma was suggested but refused and the patient assured us he was happy to continue with multiple drops and that he was managing well despite some occasional difficulties. Follow-ups continued uneventfully on a regular basis from 2016 to 2019.

In 2019, the patient presented again at eye casualty, this time with Herpes Simplex Keratitis (HSK) in the left eye and typical confluent vesicles in the thoracic area of his back respecting the midline suggestive of shingles. Examination of the LE cornea found dendritic ulcer in the 5 o'clock position that stained with fluorescein. Additionally, there was loss of corneal sensation and conjunctival hyperemia. Anterior chamber was quiet. The patient was started on Acyclovir 800 mg tablets five times daily and Acyclovir ointment five times daily. Glaucoma drops and lubricants to be continued as before.

One month later, the dendritic ulcer in the left eye had healed but both eyes had developed severe dry eye disease. Both eyes showed significant blepharitis and meibomian gland disease. Tear breakup time was less than 1 second. Irregular fluorescein uptake and generalized epithelial erosions were seen. Despite the right eye not being involved with the HSK, it manifested with equal amplitude and intensity of inflammation. It was felt that this was likely due to a number of factors including the long-term use of multiple eye drops and neuropathy in the left eye.

On follow-up shortly afterward, the previously clear graft in the right eye became hazy at the graft–host interface with signs of vascularization, thinning and limbal inflammation in the 3 and 6 o'clock positions. Topical steroids were carefully re-introduced to the right eye along with a generous lubricants program and punctal plugs for both eyes in an attempt to combat potential rejection of the graft.

The patient had eventually been persuaded to remove the scleral contact lens in the right eye in order to fully assess the intraocular pressures and corneal status. Pressures rose again to RE 35 mmHg and LE 34 mmHg (Goldmann) and optic nerves showed significant

progression with C: D ratio 0.8 both eyes with 360° thinning of the neural retinal rim. Optical coherence tomography confirmed the glaucomatous changes. It was not possible to obtain visual fields due to poor vision and tremors. The patient was offered a drainage device implant but still categorically refused surgical management. Therefore, in order to manage both the glaucoma and the ocular surface disease, his treatment regimen was updated to hourly preservative free ocular lubricants, Fluorometholone (FML) 0.1% four times daily and doxycycline 100 mg once daily to reduce the severity of the ocular surface inflammation. His glaucoma drops were all changed to a preservative free version.

Pressures reduced to RE 22 mmHg and LE 23 mmHg (Goldmann). The patient was still living alone; however, he was now unable to wear the right contact lens due to the issues with the graft and he did not have a new left lens ordered due to the recent HSK infection. His vision was therefore significantly reduced (RE 6/24 and LE counting fingers), and he was advised he must discontinue driving. The patient was struggling with existing mental health issues and became angry and distressed as this loss of independence and over time became depressed and struggled to care for himself and maintain adequate hygiene.

In order to improve the patient's quality of life as much as possible a new contact lens fitting with the contact lens specialist was arranged. The patient was sent for full medical review of his asthma, diabetes, renal and cardiac status to ensure all were being managed optimally. Nursing and occupational therapy consultations were also organized to help find other ways for the patient to manage and remain independent.

Outcome and follow-up

On recent follow-up the patient's eyes have stabilized. The pressures remain in the low 20 s and C: D ratio is 0.85 RE and 0.9 LE with no further progression. With new scleral contact lenses his VA is RE 6/36 and LE 6/15. He is still on multiple eye drops and medications but is able to remain living independently and feels more able to cope. He is followed up every four months and always attends his appointments but has remained firm in his decision not to undergo any surgical treatment for his eyes.

DISCUSSION

The patient in this case has a history of chronic kidney disease (CKD) and keratoconus. As there was not a full history available, we do not know when these conditions were diagnosed but, interestingly, a recent study in 2021 discovered a link between them and found that male patients with keratoconus are 1.36 times more likely to be diagnosed with CKD [4]. Wong et al. [5] also suggest

an association between CKD and glaucoma, cataract, macular degeneration, and ocular surface disease and suggest that further understating of this may enable development of future treatments for both kidney and ocular disease. Certainly, careful consideration of the ocular surface needs to be made when managing glaucoma with or without a positive history of CKD.

There are associations between many systemic and ocular conditions, for example, diabetes leads to a significantly higher risk of glaucoma as does systemic hypertension [6, 7]. Parkinson's disease has a higher incidence of dry eye disease and asthma is also associated with higher risk of dry eye [8, 9]. Therefore, we must consider all the factors and look at every patient as a whole to ensure optimal management of all their disorders; systemic, ocular and psychological.

CONCLUSION

This case shows the true life complexity that is often seen in ophthalmology. There are few patients who only have a single disorder that requires treatment. More often than not, treatment for one disease will lead to complications in another. With this patient, too much pushing for surgery would have alienated him and it shows we must be able to adapt and work with the patient to build trust. Careful and diplomatic management of his conditions meant he would be happy to attend his appointments and try his best to be compliant with an increasingly difficult schedule of eye drops and tablets to follow.

REFERENCES

1. Sharif R, Bak-Nielsen S, Hjortdal J, Karamichos D. Pathogenesis of keratoconus: The intriguing therapeutic potential of prolactin-inducible protein. *Prog Retin Eye Res* 2018;67:150–67.
2. Carracedo G, Recchioni A, Alejandro-Alba N, et al. Signs and symptoms of dry eye in keratoconus patients: A pilot study. *Curr Eye Res* 2015;40(11):1088–94.
3. Weinreb RN, Aung T, Medeiros FA. The pathophysiology and treatment of glaucoma: A review. *JAMA* 2014;311(18):1901–11.
4. Jan RL, Weng SF, Wang JJ, Chang YS. Association between chronic kidney disease and the most common corneal ectasia disease (keratoconus): A nationwide cohort study. *BMC Nephrol* 2021;22(1):109.
5. Wong CW, Wong TY, Cheng CY, Sabanayagam C. Kidney and eye diseases: Common risk factors, etiological mechanisms, and pathways. *Kidney Int* 2014;85(6):1290–302.
6. Zhao YX, Chen XW. Diabetes and risk of glaucoma: Systematic review and a meta-analysis of prospective cohort studies. *Int J Ophthalmol* 2017;10(9):1430–5.
7. Katsi V, Marketou M, Vlachopoulos C, et al. Impact of arterial hypertension on the eye. *Curr Hypertens Rep* 2012;14(6):581–90.

8. Biousse V, Skibell BC, Watts RL, Loupe DN, Drews-Botsch C, Newman NJ. Ophthalmologic features of Parkinson's disease. *Neurology* 2004;62(2):177–80.
9. Huang YC, Chan WC, Wang JD, Fu LS, Tsan YT. Association between dry eye disease and asthma: A nationwide population-based study. *Peer J* 2018;6(1):e5941.

Acknowledgments

Thank you to the nursing and technician staff involved with seeing this patient.

Author Contributions

Gayathri Sreekanth – Conception of the work, Acquisition of data, Revising the work critically for important intellectual content, Final approval of the version to be published, Agree to be accountable for all aspects of the work in ensuring that questions related to the accuracy or integrity of any part of the work are appropriately investigated and resolved

Nicky Jones – Design of the work, Drafting the work, Revising the work critically for important intellectual content, Final approval of the version to be published, Agree to be accountable for all aspects of the work in ensuring that questions related to the accuracy or integrity of any part of the work are appropriately investigated and resolved

Guarantor of Submission

The corresponding author is the guarantor of submission.

Source of Support

None.

Consent Statement

Written informed consent was obtained from the patient for publication of this article.

Conflict of Interest

Authors declare no conflict of interest.

Data Availability

All relevant data are within the paper and its Supporting Information files.

Copyright

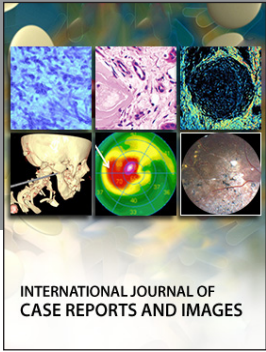
© 2022 Gayathri Sreekanth et al. This article is distributed under the terms of Creative Commons Attribution License which permits unrestricted use, distribution and reproduction in any medium provided the original author(s) and original publisher are properly credited. Please see the copyright policy on the journal website for more information.

Access full text article on
other devices



Access PDF of article on
other devices





INTERNATIONAL JOURNAL OF CASE REPORTS AND IMAGES



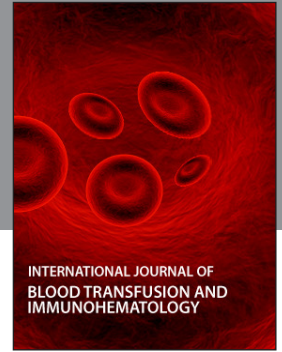VIDEO JOURNAL OF CLINICAL RESEARCH



VIDEO JOURNAL OF BIOMEDICAL SCIENCE



INTERNATIONAL JOURNAL OF HEPATOBILIARY AND PANCREATIC DISEASES



INTERNATIONAL JOURNAL OF BLOOD TRANSFUSION AND IMMUNOHEMATOLOGY



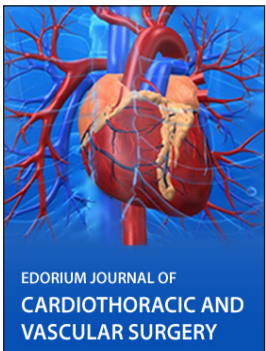
EDORIUM JOURNAL OF OPHTHALMOLOGY



Submit your manuscripts at
www.edoriumjournals.com



EDORIUM JOURNAL OF MEDICINE



EDORIUM JOURNAL OF CARDIOTHORACIC AND VASCULAR SURGERY



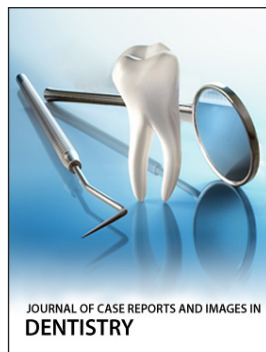
JOURNAL OF CASE REPORTS AND IMAGES IN ORTHOPEDICS AND RHEUMATOLOGY



EDORIUM JOURNAL OF PSYCHOLOGY




EDORIUM JOURNAL OF CELL BIOLOGY



JOURNAL OF CASE REPORTS AND IMAGES IN DENTISTRY



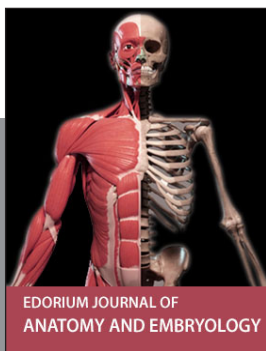
EDORIUM JOURNAL OF CANCER



EDORIUM JOURNAL OF PSYCHIATRY



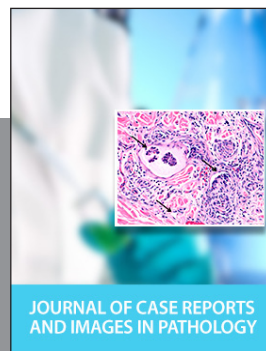JOURNAL OF CASE REPORTS AND IMAGES IN INFECTIOUS DISEASES



EDORIUM JOURNAL OF ANATOMY AND EMBRYOLOGY



EDORIUM JOURNAL OF SURGERY



JOURNAL OF CASE REPORTS AND IMAGES IN PATHOLOGY



EDORIUM JOURNAL OF ANESTHESIA